

## Axiographic findings in patients undergoing orthodontic treatment with and without premolar extractions

Wolfgang Heiser\*, Martin Stainer\*\*, Hans Reichegger\*\*, Andreas Niederwanger\*\* and Siegfried Kulmer\*\*

\*Private Practice, Innsbruck, \*\*Department of Preventive and Restorative Dentistry, Leopold-Franzens-University of Innsbruck, Austria

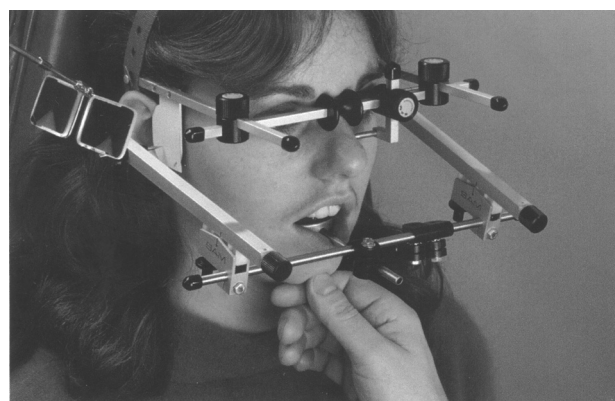
**SUMMARY** Mechanical axiography was performed on 49 (37 female, 12 male) patients prior to orthodontic treatment, after removal of the fixed appliance, and at the end of retention. Twenty-five subjects (mean age 12.8 years) underwent orthodontic treatment without premolar extractions (group 1) and 24 subjects (mean age 13.5 years) with premolar extractions (group 2). The axiographic tracings of the protrusive movements were analysed using a digitizer and specially designed software.

A statistically significant increase ( $P < 0.05$ ) in the values for horizontal condylar inclination (HCI) was found for both groups over the entire observation period. Group 1 showed a higher increase ( $P < 0.05$ ) between the beginning of treatment and removal of the brackets, and group 2 between bracket removal and the end of retention. At the end of retention, a similar increase in HCI values was found for both groups. Over the observation period, the frequency of pathological axiographic findings decreased, which seems to be a positive effect of orthodontic treatment.

### Introduction

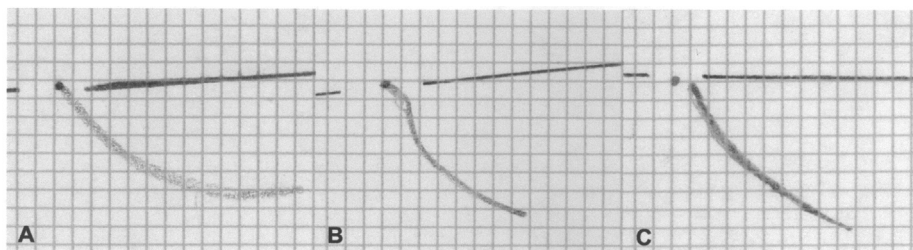
Axiography is characterized as an orthopaedic investigation of the stomatognathic system with instrumental assistance. Axiography records hinge axis movements of the temporomandibular joints (TMJs) (Campion, 1905; Lee, 1969; Slavicek and Mack, 1982; Slavicek, 1988). These recordings are made by means of a stylus on graph paper attached to parasagittal flags (Figures 1 and 2). The recordings are orientated to the axis orbital plane (AOP) which connects the terminal hinge axis and the left incisura infraorbitalis. The most valuable use of axiography is in the diagnosis of mandibular movements. Axiography also allows individual, skull-related mounting of the upper cast. Setting the recorded tracings in relation to the AOP provides data for individual adjustment of dental articulators and allows individualized dynamic analysis and treatment planning. The importance of axiography as a useful aid for the documentation of the treatment process has been shown in several investigations (Heiser and Slavicek, 1986; Slavicek and Kulmer, 1987; Grunert and Krenkel, 1991; Kulmer, 1993). Equally, the accuracy of measurements and the reliability of mechanical axiography have been investigated and proved to be adequate (Slavicek, 1988; Miller *et al.*, 1995; Bernard *et al.*, 1996; Stainer *et al.*, 1998; Hilbe *et al.*, 2000).

The relevance of an axiographic investigation prior to any dental treatment, as a documentation of the current functional state of the stomatognathic system, is often underestimated. Functional disturbances can be documented before any dental treatment. In many



**Figure 1** The recording apparatus. The face bow is attached to the patient's cranium. The registration bow is attached with articulation plaster and a clutch to the lower teeth. For localization of the terminal hinge axis, a distinct pressure is exerted on the chin to guide the mandible into a reproducible reference position. A magnifier, seen on the right side of the patient, is used for greater ease and accuracy. On the left side of the patient is the pointer for the left incisura infraorbitalis (third reference point). The pin is then changed for a telescoping dial gauge with a writing pin to record the uninhibited protrusive and retrusive movements of the patient.

cases, the major aim of orthodontic treatment is aesthetic and functional aspects of a pre-operative diagnosis programme are kept to a minimum. In cases of TMJ disorders after completion of orthodontic treatment, problems may be considered to be iatrogenic or in close connection with the treatment. The purpose of this study was to document functional parameters of the TMJs by means of mechanical axiography prior, during,



**Figure 2** Protrusive recording drawn on graph paper attached to the parasagittal flags by means of a stylus. The axis orbital plane is drawn on the recording after the investigation using a special ruler. (a) A healthy tight connection of condyle and disc. The protrusive movement starts out of centric relation (hinge axis point) with a distinct caudal convexity of the recorded line. (b) Looseness between condyle and disc. Out of a retruded position the hinge axis moves forward in a flat manner, the disc is centred on the condyle at its thinnest point and a normal, downward convex registration is seen (see also Fig. 10). (c) Registration of the hinge axis position with slight pressure on the chin (point to the left). The patient opens their mouth, and with pressure on the jaw angles in a forward and upward direction, the patient performs retrusive and protrusive movements. Through this pressure the condyle stays centred at the thinnest part of the disc. The distance between the hinge axis point and the end of the retrusive recording shows the looseness in the lower compartment of the temporomandibular joint.

and after orthodontic treatment, with and without premolar extractions.

### Materials and methods

Mechanical axiographic tracings of protrusive movements of 49 consecutive patients from an orthodontic practice were analysed in this study. The sample was divided into two groups: non-extraction (group 1) and extraction of premolars (group 2). Group 1 consisted of 25 patients, 19 females and six males, with a mean age at the beginning of treatment of 12 years 10 months. Group 2 comprised 24 patients, 18 females and six males, with a mean age before treatment of 13 years 7 months. The indications for extraction of premolars in group 1 were carious destruction (one case), arch length discrepancy with an open bite tendency (seven cases), severe crowding (12 cases), and compensation for congenitally missing teeth (five cases).

All selected patients underwent a thorough pre-operative diagnostic programme (Kulmer, 1980), including a general medical questionnaire and clinical and instrumental functional analysis. The instrumental functional analysis included mechanical axiography, skull- and joint-related mounted casts in an individually programmed dental articulator, and the use of a mandibular position indicator (Kulmer, 1977; Slavicek and Mack, 1979). The first axiography was performed in the diagnostic phase (A1). Further axiographic investigations were carried out after appliance removal (A2) and at the end of retention (A3). All axiographic investigations were performed by the same experienced operator (HW). For localization of the terminal hinge axis points, slight pressure was exerted on the chin to guide the mandible into a reference position. This was necessary to obtain reproducible positions of the terminal

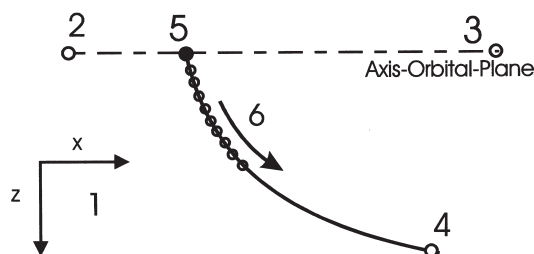
hinge axis points at different investigation times. As the recordings are orientated to the AOP, the exact localization of all three reference points was of prime importance for quantitative evaluation. All functional movements recorded were performed by the patients themselves without any manipulation by the operator and without any contact of maxillary teeth and the mandibular clutch. The age of the patients and the intervals between the investigations are shown in Table 1.

For analysis, the protrusive recordings were magnified 100 per cent with a photocopier (Ectachrome E-90, Kodak, Rochester, USA). The magnified records were fixed on a plane acrylic plate on a digitizer (Gamma, Klosterneuburg, Austria). On the enlarged graph paper a distance of 10 mm was digitized first on the *x* and *z* co-ordinates (Figure 3). This allowed the programme to set the scale and, if necessary, rectify any distortion. The two most separated points of the AOP were first digitized and the AOP was defined as the reference plane. Next, the endpoint of the protrusive line was digitized. Starting at the hinge axis point, additional measuring points were set at intervals of 0.5 mm along the path of the functional protrusive tracing. Individually

**Table 1** Age (years) and times of investigation.

Group	Time of investigation	Mean age (SD)	Interval between investigations (years)
1	A1	12.8 (2.1)	
	A2	14.8 (2.1)	A1–A2 = 1.8
	A3	15.8 (1.1)	A1–A3 = 2.9
2	A1	13.5 (4.0)	A1–A2 = 2.0
	A2	15.2 (3.0)	A2–A3 = 1.6
	A3	17.2 (3.1)	A1–A3 = 3.7

SD, standard deviation.



**Figure 3** Sequence of the measurement points digitized: 1, determination of scale; 2, 3, most separated points at the axis orbital plane; 4, endpoint of the protrusive line; 5, hinge axis point; 6, measurement points along the protrusive line.

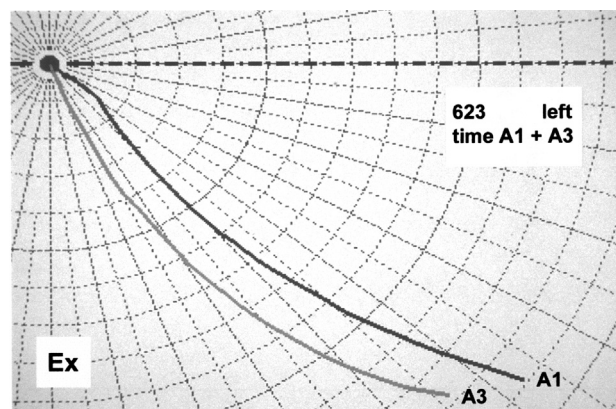
designed software allowed the functional lines to be digitized and the values of the horizontal condylar inclination (HCI) for each millimetre of the protrusive pathway were calculated. The HCI was defined as the angle between the condylar pathway and the AOP in degrees. The measuring accuracy of the system was expressed as the standard deviation for repeated measurements ( $\pm 0.15$  degrees). The software calculated the HCI values for the following statistical analysis. For data management, the statistical software SPSS for Windows (SPSS Inc., Chicago, Illinois, USA) was used and for statistical analysis the Mann-Whitney *U*-test, the *t*-test for paired samples, and the principal component analysis.

Furthermore, the axiographic recordings could be displayed on the computer screen for qualitative analysis. An additional feature allowed superimposition of all three axiographic recordings, and of the left and right sides, for each patient. Thus, the tracings at different time points could be compared with each other (Figure 4).

## Results

### *Type and frequency of pathologically altered axiographic recordings*

The pathologically altered recordings were classified according to Heiser and Slavicek (1986). This classification subdivides nine groups of TMJ disorders ranging from 'normal joint' to 'permanent bilateral internal derangement with morphological changes of the condyle'. In the majority of the subjects, various forms of ligamentary looseness in the lower compartment of the joints were found. In two patients, anterior displacement of the disc with repositioning was diagnosed at the beginning of treatment. Pathological findings at least at one time point of the investigation were found in 56 per cent of all investigated joints. Thirty-four per cent showed pathologically altered recordings at all time points and in 11 per cent a development from a normal to a pathological finding or reverse was observed. Table 2



**Figure 4** A computer display of digitized tracings of the left temporomandibular joint recorded at different times of the investigation. Starting at the hinge axis point, the dark axiographic tracing (A1), on the right side, shows a pathological initial anterior convexity (beginning of an internal derangement). The grey tracing (A3), on the left side, is normal. Between treatment times A1 and A3 the joint has recovered and in addition to this a steepening of the horizontal condylar inclination can be observed, enabling improved disclusion of the posterior teeth.

**Table 2** Frequency of pathological axiographic findings (%;  $n = 98$ ) in groups 1 and 2 over the entire observation period.

	A1	A2	A3
Group 1	47	36	27
Group 2	53	29.5	35.2

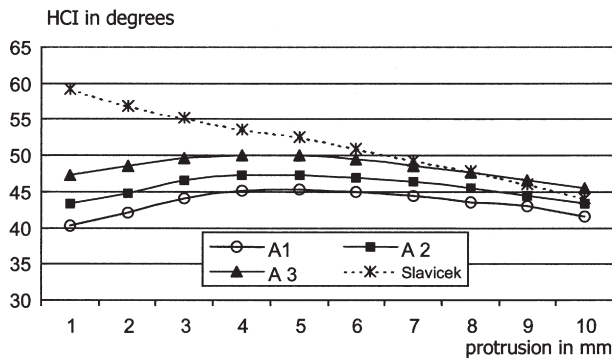
gives the frequencies of the pathological findings in both groups. In group 1 a continuous decrease in pathological findings was observed over the whole treatment period. In group 2 a distinct decrease between A1 and A2 was followed by an increase between A2 and A3. Between A1 and A3 the frequency of pathological findings was reduced in both groups by approximately the same amount.

### *Mean HCI values of the whole sample investigated*

The mean HCI values at various times (A1, A2, A3) measured at each millimetre between 1 and 10 mm of the protrusive movement for all joints (right and left) and both groups are shown in Figure 5. The data demonstrated a general increase in the values of HCI between A1 and A3. The Mann-Whitney *U*-test showed no statistically significant increase between A1 and A2 ( $P > 0.05$ ) or between A2 and A3 ( $P > 0.05$ ). In contrast, the increase in HCI over the entire treatment time between A1 and A3 was statistically significant ( $P < 0.05$ ).

### *Mean HCI values of groups 1 and 2*

An increase in HCI values was observed for both groups. Overall, the greatest difference was found between A1

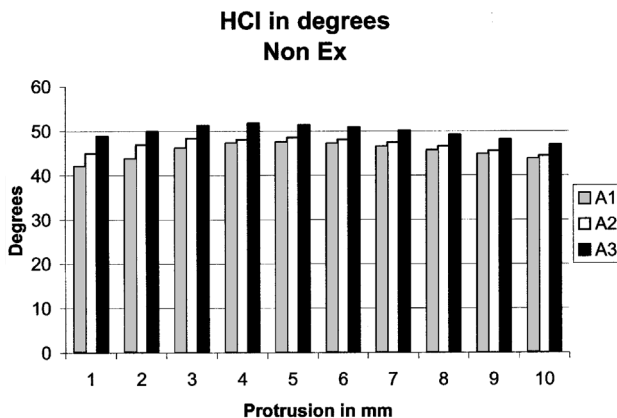


**Figure 5** Horizontal condylar inclination (HCI) values of all joints investigated ( $n = 98$ ). Each line represents the mean values for both groups and the right and the left sides at A1, A2, and A3. The HCI values of healthy young adults investigated by Slavicek (1984) are inserted for comparison (dotted line). The increase in HCI between A1 and A3 was statistically significant ( $P < 0.05$ ). The pathological recordings are not separated. This results in flatter values during the first 5 mm of protrusive movement.

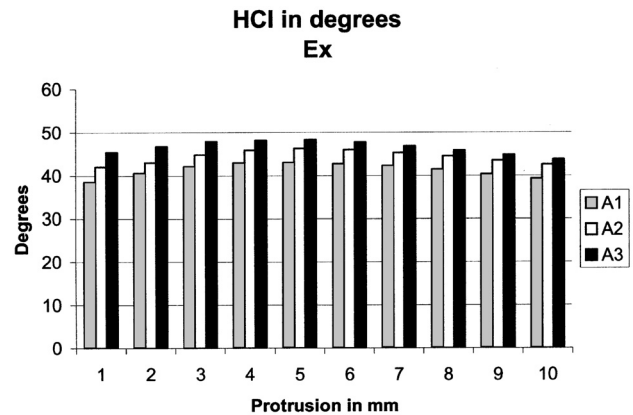
and A3. A closer analysis of group 1 revealed an additional continuous decrease in the HCI difference between A1 and A2 during the first 4 mm of protrusive movement while the difference between A2 and A3 remained constant (Figure 6). In contrast, a continuous decrease in the difference between A2 and A3 was visible for the complete protrusive movement in group 2, while the difference between A1 and A2 remained constant (Figure 7).

#### Mean HCI values of groups 1 and 2 with and without pathological axiographic findings

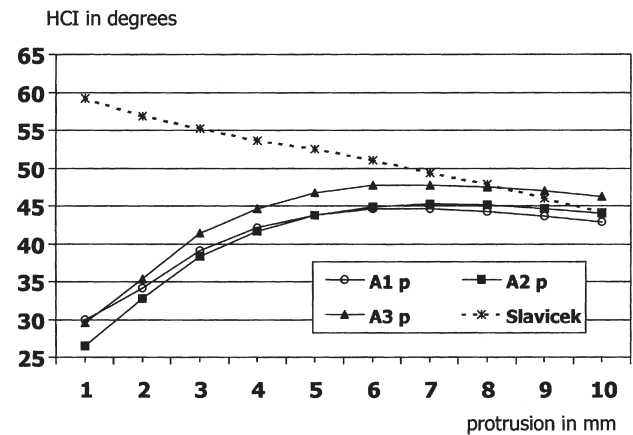
A separation of the recordings with and without pathological findings showed a remarkable difference in the initial HCI values (Figures 8 and 9). For the first 5 mm of protrusive movement, the HCI values of the pathologically altered tracings were significantly



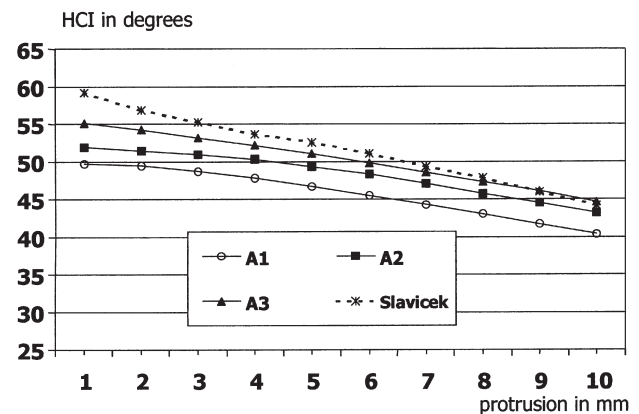
**Figure 6** Horizontal condylar inclination values for group 1 (non-extraction group). Investigation dates A1, A2, and A3 in order of appearance from left to right.



**Figure 7** Horizontal condylar inclination values for group 2 (extraction group). Investigation dates A1, A2, and A3 in order of appearance from left to right.



**Figure 8** Mean horizontal condylar inclination (HCI) values of both groups with pathological findings. A remarkable flattening of the HCI at the initial 5 mm of the protrusive pathway is obvious. At the endpoint of the movement, normal HCI values are reached. The increase between A1 and A3 can only be observed at the end of the protrusive movement.



**Figure 9** Mean horizontal condylar inclination values of both groups without pathological findings. Again an increase in the values of approximately 5 degrees can be seen between A1 and A3. The values measured at A3 correspond to a high degree with the values of Slavicek (1984).



( $P < 0.05$ ) lower than those of the non-pathological tracings. A general increase in HCI values from A1 to A3 was confirmed for both the pathological and non-pathological recordings.

#### *Symmetrical and asymmetrical HCI values at different investigation times*

The percentage of symmetrical and asymmetrical HCI values between the right and left sides at different time points is summarized in Table 3. An increase in symmetry from A1 to A2 and a decrease to A3 were observed for both groups. The fraction of symmetrical findings at A2 was greater in group 1. The relationship between symmetry and asymmetry was approximately the same at the beginning and end of treatment.

### Discussion

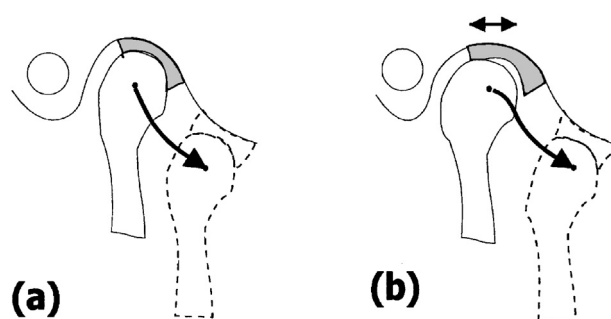
Because axiographic recordings represent movements of the hinge axis, interpretation of the tracings must be undertaken with care. The protrusive mandibular movements were performed in the sagittal plane by the patients themselves, without any manipulation by the operator and with no contact of the upper teeth and the clutch on the lower teeth. The parasagittal recordings correlate to a high degree with the movements of the hinge axis and with the movement of the condyles. According to the quantity and quality of the recordings, conclusions can be drawn concerning the form of the condylar pathway, the condition of the connective tissues, and the functional relationship between the condyle and disc.

The most conspicuous result in this investigation was the increase in HCI values during the entire observation period of approximately 3 years. The increase from A1 to A3 was statistically significant ( $P < 0.05$ ) and could be observed for each millimetre of protrusive movement and for both groups (Figure 5). The pathologically altered recordings showed initial flatter HCI values. This was due to a ligamentary looseness of the TMJs which allowed a more horizontal movement in the lower compartment of the joint at the beginning of protrusion

instead of a strict hinge movement only. It seems that with a protrusive pathway of 6 mm the disc is centred at the thinnest part in most subjects and the HCI values reach those of the non-pathological recordings (Figures 8 and 9).

Due to the tight contact of the condyle–disc complex itself and with the glenoid fossa in healthy joints, the tracings of the hinge axis reflect the contour of the condylar pathway. Forty-four per cent of all joints investigated showed normal axiographic recordings at all time points. Thus, a change in the form of the glenoid fossa and/or the condyle will result in an altered recorded tracing and HCI. For the HCI values, the initial segment of the tracing in affected joints cannot be interpreted, but the terminal pathway, when the disc is centred, could be evaluated (Figures 10a, b).

As predominant factors for the increase in HCI, growth, age, and sex must be considered. Slavicek (1984) stated that 90 per cent of TMJ development is completed at 10 years of age. Van der Linden (1984) came to the conclusion that at 6 years of age 90 per cent of the calvaria and the basicranium have reached their final form. Apart from this, the process of remodelling must be discussed as a growth-independent life-long process and can be observed in all osseous structures. Mongini (1975) reported that remodelling above all can be found in the TMJs (Grunert, 1995; Grunert *et al.*, 2000). The mean age of group 1 ranged between 12.8 years at A1 and 15.8 years at A3 and group 2 between 13.5 and 17.2 years. Due to this, an acceleration of growth during puberty must be considered as a major reason for the increasing HCI in both groups from A1 to A3. With regard to the age at which this growth spurt occurs, great individual variations can be found. According to Van der Linden (1984), the beginning of pubertal growth acceleration must be



**Figure 10** A schematic diagram of the protrusive movement of the condyle–disc complex in healthy joints and those with ligamentary looseness in the lower compartment. (a) Healthy joint: during complete protrusive movement the condyle is centred at the thinnest part of the disc resulting in a regular recording. (b) Compromised joint: no tight contact between condyle and disc and initial horizontal movement of the condyle. The result is a recording with an initial anterior convexity and flat horizontal condylar inclination values. At the end of the movement the condyle is centred at the thinnest part of the disc.

**Table 3** Comparison of symmetry and asymmetry (%) between right and left axiographic patterns in groups 1 and 2 at investigation times A1–A2–A3.

Group	Time	Symmetry	Asymmetry
1	A1	42	58
	A2	68.4	31.6
	A3	42.1	57.9
2	A1	41.2	58.8
	A2	53	47
	A3	41.2	58.8

supposed between 9 and 13 years for girls and between 11 and 15 years for boys. From this point of view, a growth spurt in puberty seems not to be the appropriate explanation for the HCI increment, as the greatest increase in HCI values occurred in both groups around the mean age of 15 years. As the basicranium is not included in the pubertal growth spurt, the continuous growth of the body must be accepted as the most probable cause for this evolution.

It was not the major aim of the study to compare subjects with and without orthodontic treatment. Angel (1948) and Ingervall (1972) showed a correlation between HCI and the age of patients without orthodontic treatment. So, a general trend for this HCI development can be suspected. For individual analysis of the HCI increase, both groups were investigated for symmetrical, asymmetrical, and no increase. No tendency could be shown for these relationships. An individual comparison of age showed that five patients with no increase in HCI from A1 to A3 were older than 17 years of age at A1. To make a clear statement about the influence of sex and age on growth changes, a larger sample with a homogenous distribution of females and males would be necessary.

A comparison of left and right axiographic patterns revealed a remarkable asymmetry. The greatest number of symmetrical findings was observed for both groups at A2. Particular pathologically altered recordings showed large asymmetries. In some cases the difference in HCI values between the right and left side ranged up to 15 degrees.

The development of a right-left symmetry could be made between different investigation times. A change from symmetry to asymmetry could be observed, as well as the opposite development or a steady-state of symmetry or asymmetry.

Structural asymmetries have been described in adolescents and adults by Mongini (1989). Mongini (1975) divided asymmetries of the TMJ into osseous asymmetries, asymmetries of adjacent connective tissues and those caused by a shifting of the mandible. A mandibular shift can be observed when there is a discrepancy between centric relation and maximum intercuspation. This change in the functional load is not only transduced to the condyles but also to the adjacent structures. Depending on the amount of force generated, a change in the direction of mandibular growth in adolescents and a remodelling process in adults is induced (Blackwood, 1966; Carlsson and Öberg, 1974; Mongini, 1987). As traumatic occlusal relationships frequently occur before and during orthodontic treatment, the observed asymmetries might be explained in this way. A reason for the small number of asymmetries in both groups at A2 was not obvious.

Finally, the reduction in pathological axiographic findings over the entire observation period in both groups

seems to be a positive effect of orthodontic treatment. The treatment goal in all cases was a coincidence of centric relation and centric occlusion and a sequential guidance with anterior canine dominance (mutually protected occlusion) (Kulmer, 1993; Kulmer *et al.*, 1999).

## Conclusions and clinical implications

1. Temporomandibular disorders were diagnosed by means of mechanical axiography in approximately 50 per cent of patients prior to orthodontic treatment.
2. During orthodontic treatment, a decrease in the frequency of pathologically altered axiographic tracings was observed in both groups investigated.
3. The large number of affected TMJs highlights the need for a thorough diagnosis prior to orthodontic treatment, and axiography has proved to be an important diagnostic tool.
4. A statistically significant ( $P < 0.05$ ) increase in the steepness of HCI could be shown in both groups over the observation period.

## Address for correspondence

Siegfried Kulmer  
Department of Preventive and Restorative Dentistry  
MZA  
Anichstraße 35  
A-6020 Innsbruck  
Austria

## References

- Angel E H 1948 Factors in temporomandibular joint form. *American Journal of Anatomy* 83: 223–246
- Bernard N, Utz K H, Schmitt L 1996 Zur Präzision der mechanischen Axiographie. *Deutsche Zahnärztliche Zeitschrift* 51: 469–472
- Blackwood H 1966 Adaptive changes in the mandibular joints with function. *Dental Clinics of North America* 10: 559–566
- Campion G G 1905 Some graphic records of movements of the mandible in the living subject. *Dental Cosmos* 47: 39–42
- Carlsson G, Öberg T 1974 Remodeling of the temporomandibular joints. *Oral Science Reviews* 6: 53–86
- Grunert I 1995 Die Kiefergelenke des Zahnlosen. Eine anatomische und klinische Untersuchung. Quintessenz, Berlin
- Grunert I, Krenkel Ch 1991 Vergleich axiographischer Aufzeichnungen bei operierten Progeniepatienten von präoperativ bis zu Spätkontrolle. *Österreichische Zeitschrift für Stomatologie* 88: 163–176
- Grunert I, Grubwieser G, Ulmer H 2000 Bilateral investigation of the temporomandibular joint. An autopsy study of edentulous individuals. *Journal of Oral Rehabilitation* 27: 671–681
- Heiser W, Slavicek R 1986 Die Bedeutung der klinischen und instrumentellen Funktionsanalyse in der kieferorthopädischen Praxis. *Österreichische Zeitschrift für Stomatologie* 83: 367–380
- Hilbe M, Stainer M, Niederwanger A, Kulmer S 2000 Langzeitstabilität der gelenksbezüglichen Zentrik—Eine Untersuchung mittels paraokklusaler mechanischer Achiographie. *Deutsche Zahnärztliche Zeitschrift* 55: 566–569

- Ingervall B 1972 Range of sagittal movement of the mandibular condyles and inclination of the condyle path in children and adults. *Acta Odontologica Scandinavica* 30: 67–87
- Kulmer S 1977 Die Kieferrelation im Wechselgebiß. *Österreichische Zeitschrift für Stomatologie* 74: 361–375, 398–411
- Kulmer S 1980 Grundlagen der Rehabilitation des parodontal reduzierten Gebisses. *Österreichische Zeitschrift für Stomatologie* 3: 12–16
- Kulmer S 1993 Long-term stability and occlusion. In: Hösl E, Baldauf A (eds) *Retention and long-term stability*. Hüthig, Heidelberg, pp. 47–62
- Kulmer S, Ruzicka B, Moschén I 1999 Incline and length of guiding elements in the untreated naturally grown dentition. *Journal of Oral Rehabilitation* 26: 650–660
- Lee R 1969 Jaw movements engraved in solid plastic blocks for articulator controls. Part I. Recording apparatus. *Journal of Prosthetic Dentistry* 22: 209–224
- Miller D, Kulmer S, Dumfahrt H 1995 Mechanische und elektronische Axiographie—Ein Methodenvergleich. *Informationen aus Orthodontie und Kieferorthopädie* 27: 15–23
- Mongini F 1975 Dental abrasion as a factor in remodelling of the mandibular condyle. *Acta Anatomica* 92: 292–300
- Mongini F 1987 Treatment of mandibular asymmetries during growth. A longitudinal study. *European Journal of Orthodontics* 22: 51–67
- Mongini F 1989 Schädel, Kiefer- und Gelenkorthopädie. Quintessence, Berlin
- Slavicek R 1984 Die funktionellen Determinanten des Kauorgans. Habilitationsschrift, Verlag Zahnärztlich-Medizinisches Schrifttum, Munich
- Slavicek R 1988 Clinical and instrumental functional analysis for diagnosis and treatment planning. Part 5. Axiography. *Journal of Clinical Orthodontics* 22: 656–665
- Slavicek R, Kulmer S 1987 Die Rolle des Orthodonten in der Diagnose und Therapie der Dysfunktion. *Informationen aus Orthodontie und Kieferorthopädie* 19: 137–144
- Slavicek R, Mack H 1979 Messung der Auswirkung von unterschiedlichen Okklusionsbeziehungen auf die Kiefergelenke. *Schweizer Monatsschrift für Zahnheilkunde* 89: 925–930
- Slavicek R, Mack H 1982 Der Axiograph. *Informationen aus Orthodontie und Kieferorthopädie* 14: 53–62
- Stainer M, Reichegger H, Grubwieser G, Heiser W, Kulmer S 1998 Reproduzierbarkeit der mechanischen Achiographie im Langzeitversuch. *Deutsche Zahnärztliche Zeitschrift* 8: 543–546
- Van der Linden F R G M 1984 Gesichtswachstum und faziale Orthopädie. Quintessence, Berlin

